

Kidney & Urinary Tract Ultrasound

Fatina Fadel

Hafez Bazaraa

Ultrasonography


LIVER TRANS

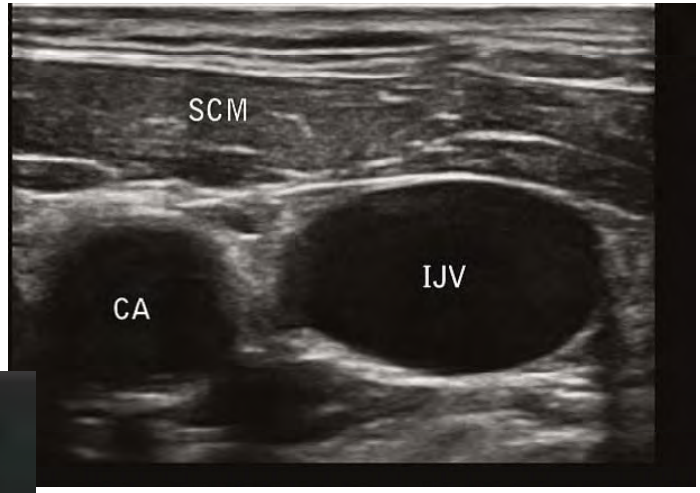
SCM
CA
IJV

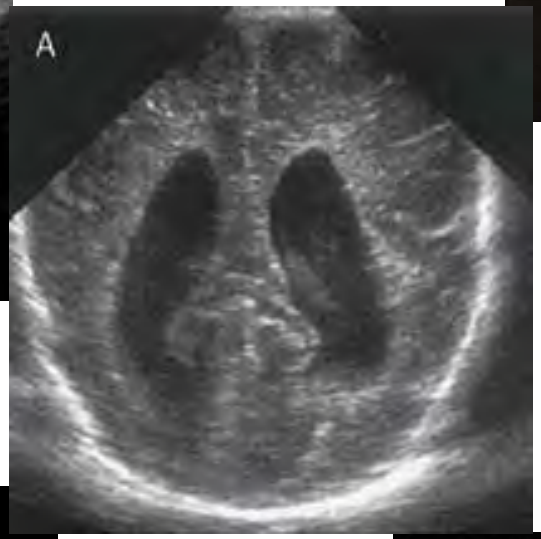
A

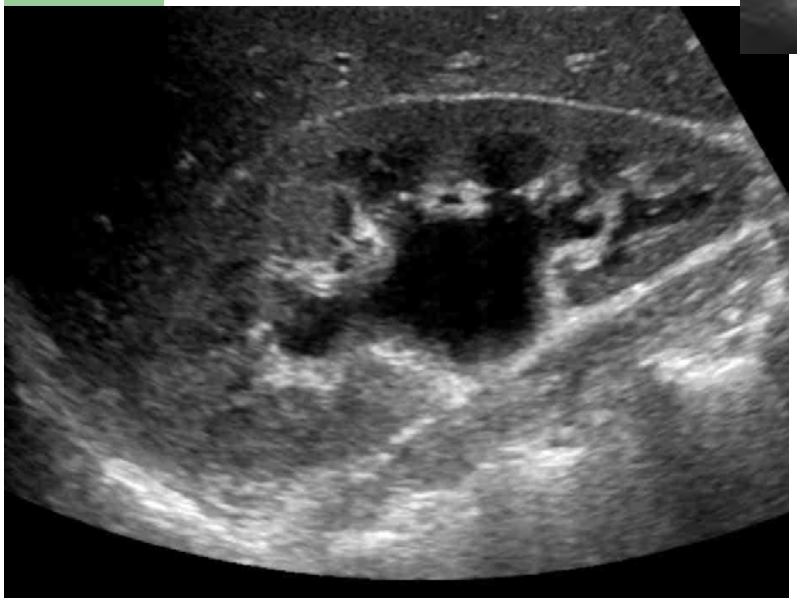

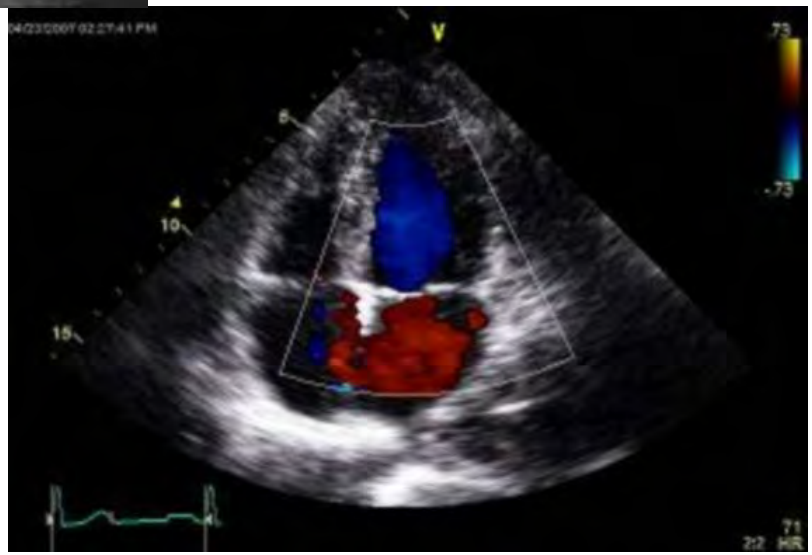
V
73
-73
5
10
15
71
HR


Vscan

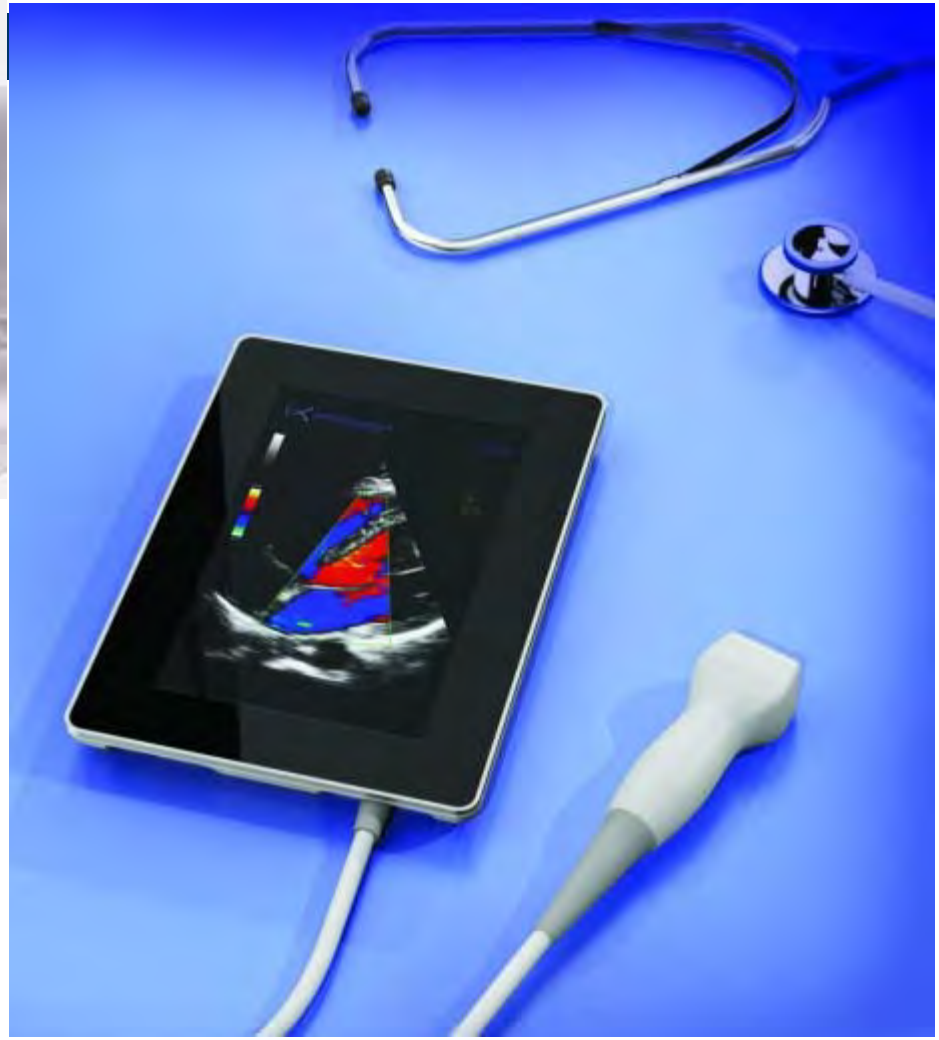

Ultrasound

- Available
- Rapid
- Inexpensive
- Painless & no sedation needed
- No adverse effects/ complications
- Can be repeated
- Useful for screening

Ultrasound

- Ultrasound has advanced from a specialized imaging technique to a bedside test & clinical examination supplement
- Ultrasound is the principal imaging modality for visualization of the kidneys & urinary tract

In a patient with renal failure ….

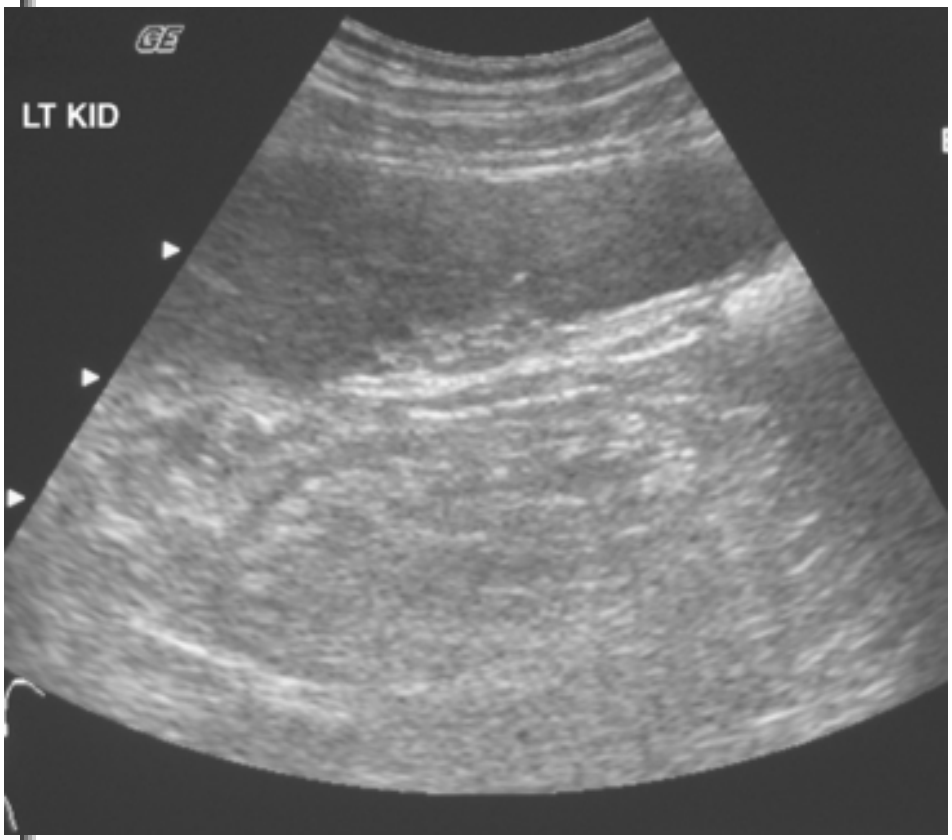

In a patient with AKI …

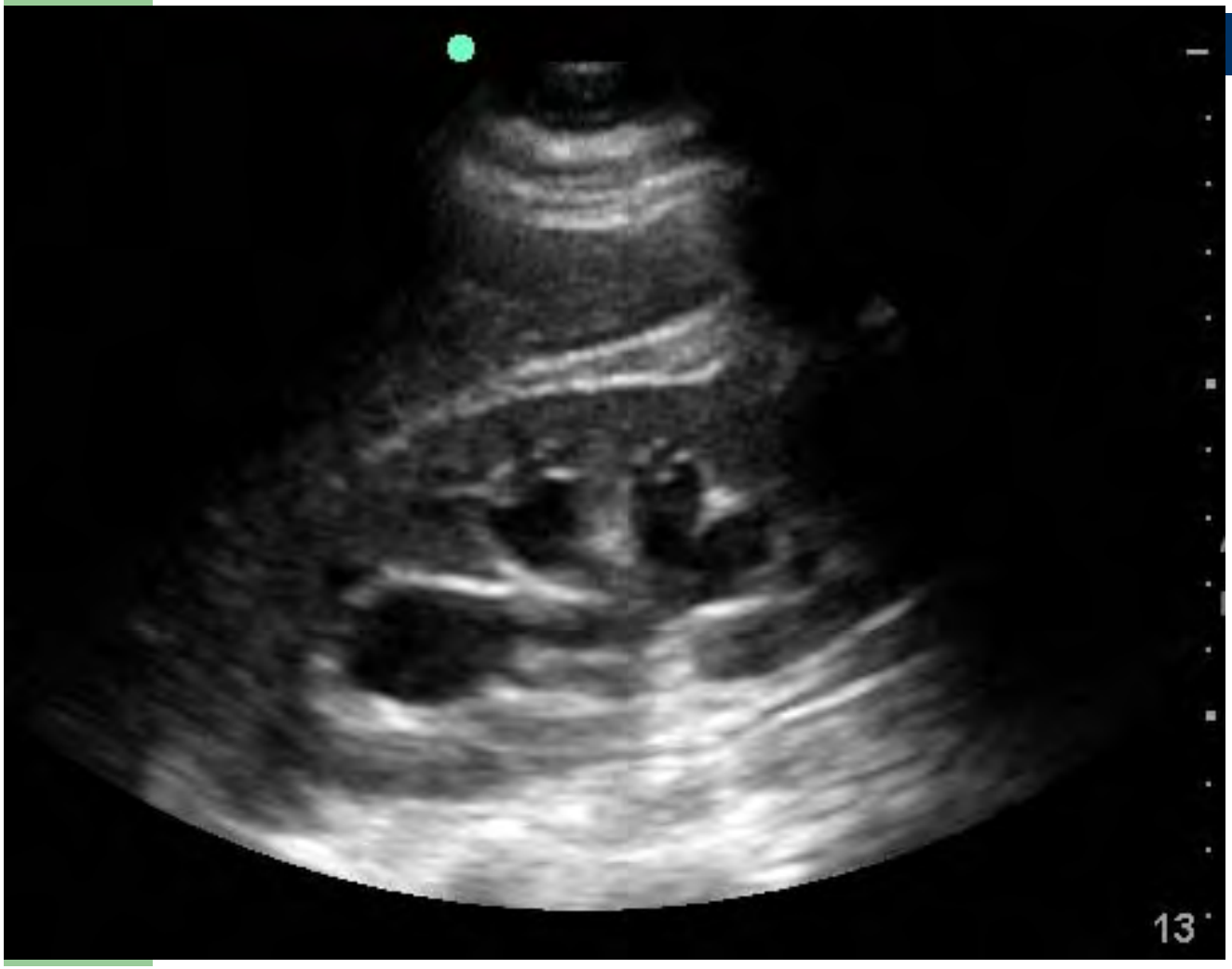

Role of US

- Confirm normal anatomical position of kidneys
- Exclude structural anomalies.
- Assess size of the kidneys and collecting systems
- Exclude renal cortical scarring.
- Exclude renal or suprarenal masses (cystic or solid)
- Assess bladder filling and emptying

Common Neonatal & Pediatric Pathology

- **Fusion Anomalies**. (horseshoe, ectopia, cross-fusion)
- **Hypoplasia or agenesis**.
- **Duplication anomalies**. (supernumerary or variants of the collecting system and uterers)
- **Congenital structural disease** (Juveline PCKD, MCDK, dysplasia)
- **Solid tumours**

Limitations

Co-operation is the biggest challenge with any pediatric study.

- If scanning a neonate, try to time the scan after a feed for best compliance.
- Full bladder if cooperative, bladder 1st (before void) if not.
- Use WARM gel

Ultrasound CANNOT exclude vesico-ureteric reflux.

EXAMINATION TECHNIQUE

Equipment & position

- **5+MHz curvilinear probe**
  - 3.5 MHz for larger adolescents
  - High frequency (superficial) linear probe 8-12 MHz ↑ resolution
- **Supine position**
  - Essential for bladder
  - May use contra-lateral with caregiver support, posterolateral imaging, for kidneys
  - Prone (if gases preclude visualization)

Scanning: Kidneys

- Confirm normal position
- Measure renal length
- Cortical thickness & echogenicity, CM differentiation, pyramids
- Cortical scars, cysts, NC
- Assess pelvis, calyces

Scan entire kidney in LS & TS, may use higher freq. probe for detailed scan of cortex & med. Pyramids

Age	Mean length (cm)	Range (±2 SD in cm)
Term newborn	4.48	3.86–5.10
2 months	5.28	3.96–6.60
6 months	6.15	4.81–7.49
1.5 years	6.65	5.57–7.73
2.5 years	7.36	6.28–8.44
3.5 years	7.36	6.18–8.54
4.5 years	7.87	6.87–8.87
5.5 years	8.09	7.01–9.17
6.5 years	7.83	6.39–9.27
7.5 years	8.33	7.31–9.35
8.5 years	8.90	7.14–10.66
9.5 years	9.20	7.40–11.00
10.5 years	9.17	7.53–10.81
11.5 years	9.60	8.32–10.88
12.5 years	10.42	8.68–12.16
13.5 years	9.79	8.29–11.29
14.5 years	10.05	8.81–11.29
15.5 years	10.93	9.41–12.45
16.5 years	10.04	8.32–11.76
17.5 years	10.53	9.95–11.11
18.5 years	10.81	8.55–13.07

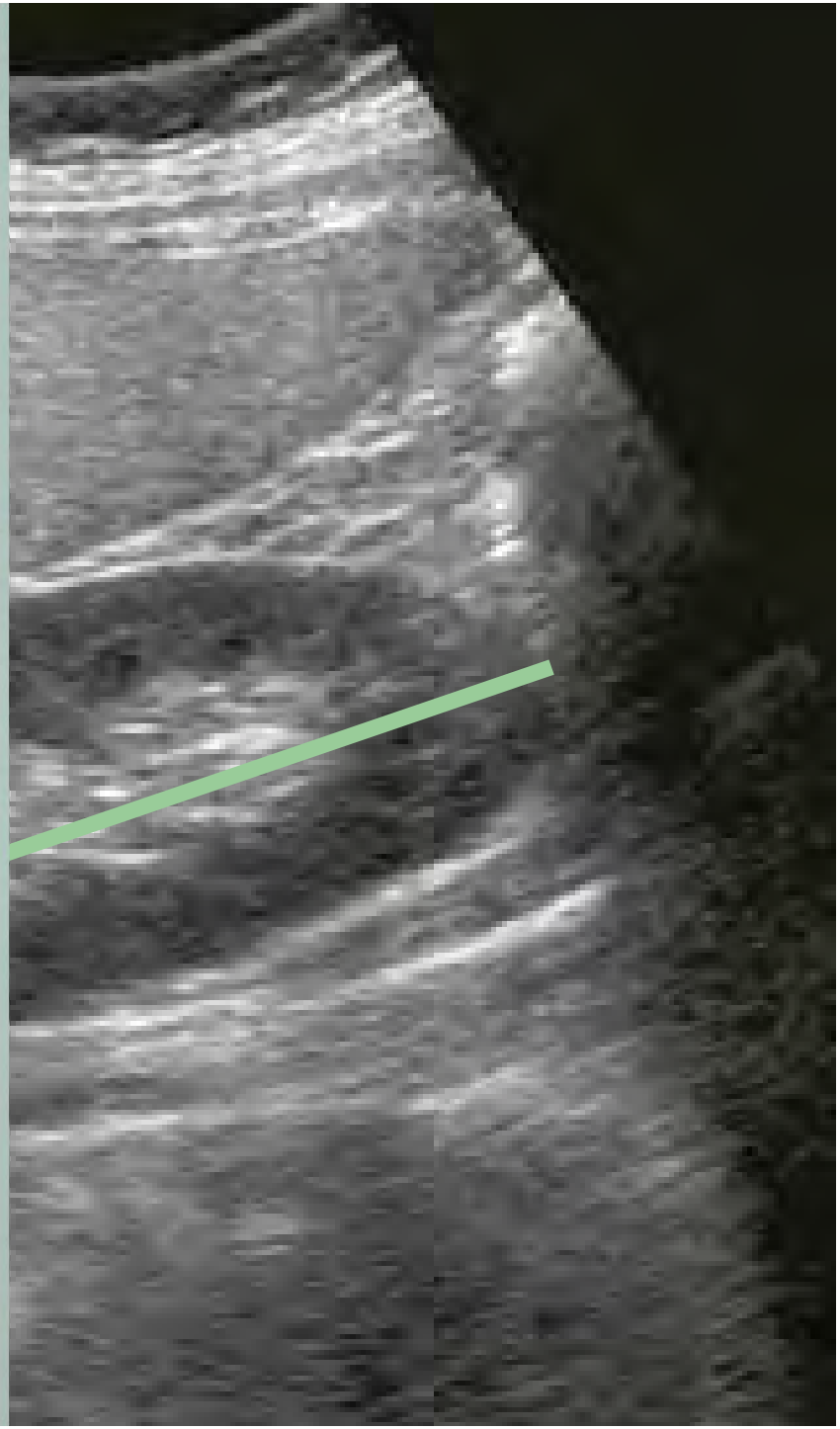

Renal length

- Supine measurement (prone underestimates)
- 2x
- Size correlates with pt height/ length more than age
- Lt kidney slightly larger (-5mm) in most cases

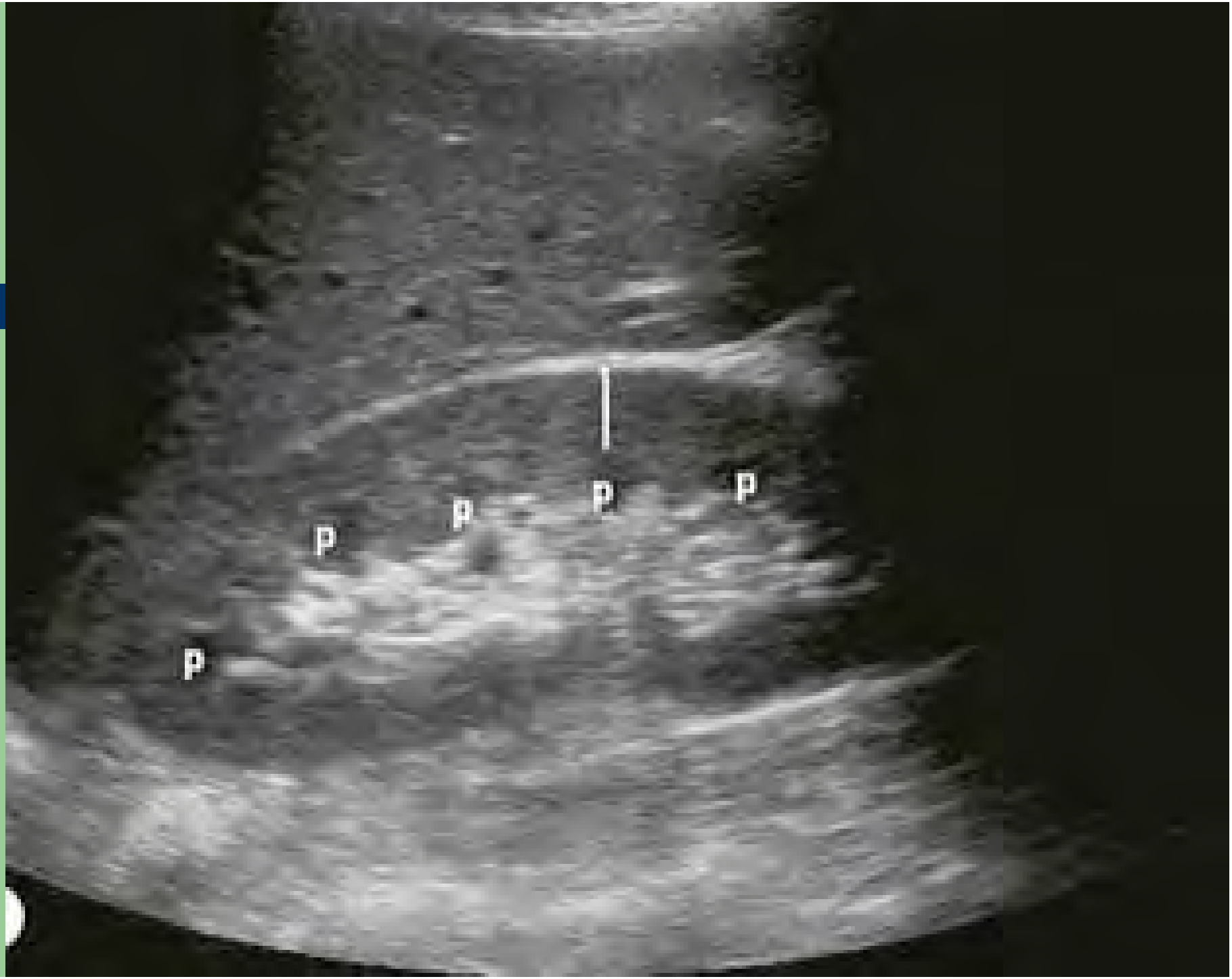
p
p
p
p
p

Normal kidney

Longitudinal section

Cross section

Renal capsule: echogenic line

Renal parenchyma: outer cortex & inner medulla pyramid

Central sinus complex: high echogenicity (vessels, fat, fibrous tissue)

Features

- The renal cortex in patients older than 6 months of age is nearly always hypoechoic relative to the adjacent liver or spleen .
- The normal medullary pyramids are (minimally) hypoechoic. The identification of these pyramids is easier with hydration of the patient and diuresis.
- The renal sinus appears as a central echogenic area. (may be minimal-decreased vs adult)
- The renal pelvis, when visible, should be 10 mm or less in AP diameter.

Neonatal kidney; 3 features

1. Echogenicity ↑↑ (↑↑ no of glomeruli).
2. Prominent hypoechoic renal pyramids (larger medullary volumes, ↓↓ CM diff). Don't misinterpret as dilated collecting system
3. Renal sinus echogenicity ↓ ↓ (paucity of echogenic pelvic/ medullary fat)

Scanning: Kidneys

- Confirm normal position
- Measure renal length
- **Cortical thickness & echogenicity, CM differentiation, pyramids**
- Cortical scars, cysts, NC
- Assess pelvis, calyces

Scan entire kidney in LS & TS, may use higher freq. probe for detailed scan of cortex & med. Pyramids

Echogenicity

Renal parenchymal disease
eg GN, Nephrotic
present as↑ echogenicity

Cortical echogenicity	
Grade 0	Less than normal liver
Grade I	Equals normal liver
Grade II	Exceeds liver; less than renal sinus
Grade III	Exceeds liver; equals renal sinus echo

Pyramids should be hypoechoic

↑ echogenicity suggests nephritis

Echogenic lines throughout➔ severe PN

Scanning: Kidneys

- Confirm normal position
- Measure renal length
- Cortical thickness & echogenicity, CM differentiation, pyramids
- Cortical scars, **cysts, NC**
- Assess **pelvis, calyces** **urolithiasis**

Scan entire kidney in LS & TS, may use higher freq. probe for detailed scan of cortex & med. Pyramids

Collecting system

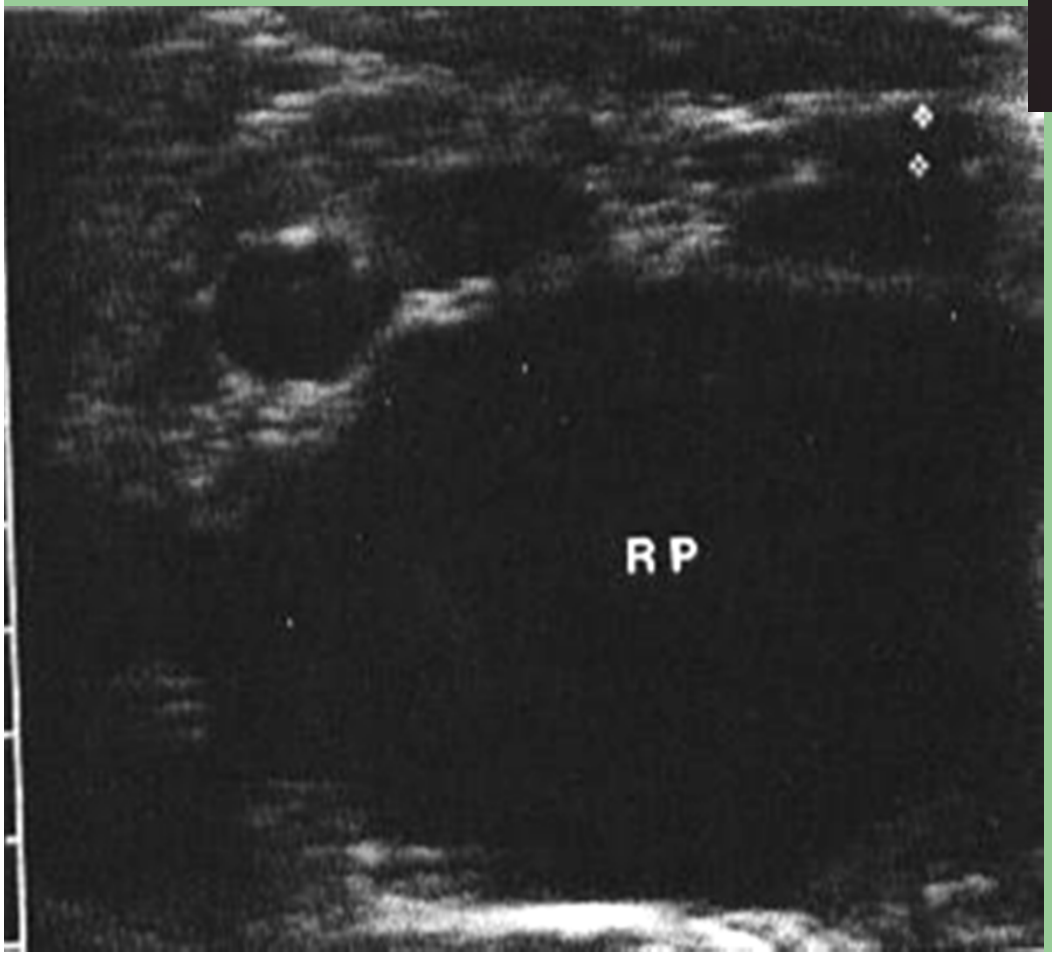

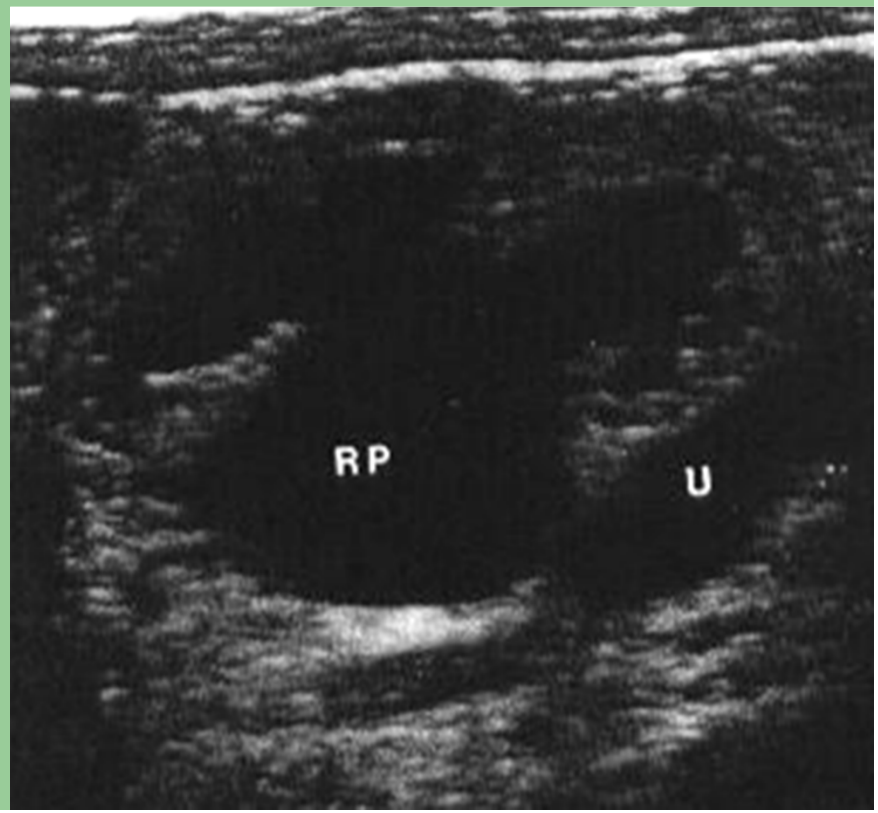

- Pelvicalyceal without ureteric dilatation → PUJO
- Intrauterine HN → post-natal scan 4-5 d not before (dehydration & low GFR may give false –ve early)

Grading of hydronephrosis

Society of fetal urology grading system for hydronephrosis	
Grade	U/S
0	No hydronephrosis
1	Only renal pelvis is seen
2	Renal pelvis & few calyces are seen
3	Virtually all calyces are seen
4	Virtually all calyces are seen + parenchymal thinning

Partial Duplex Kidney

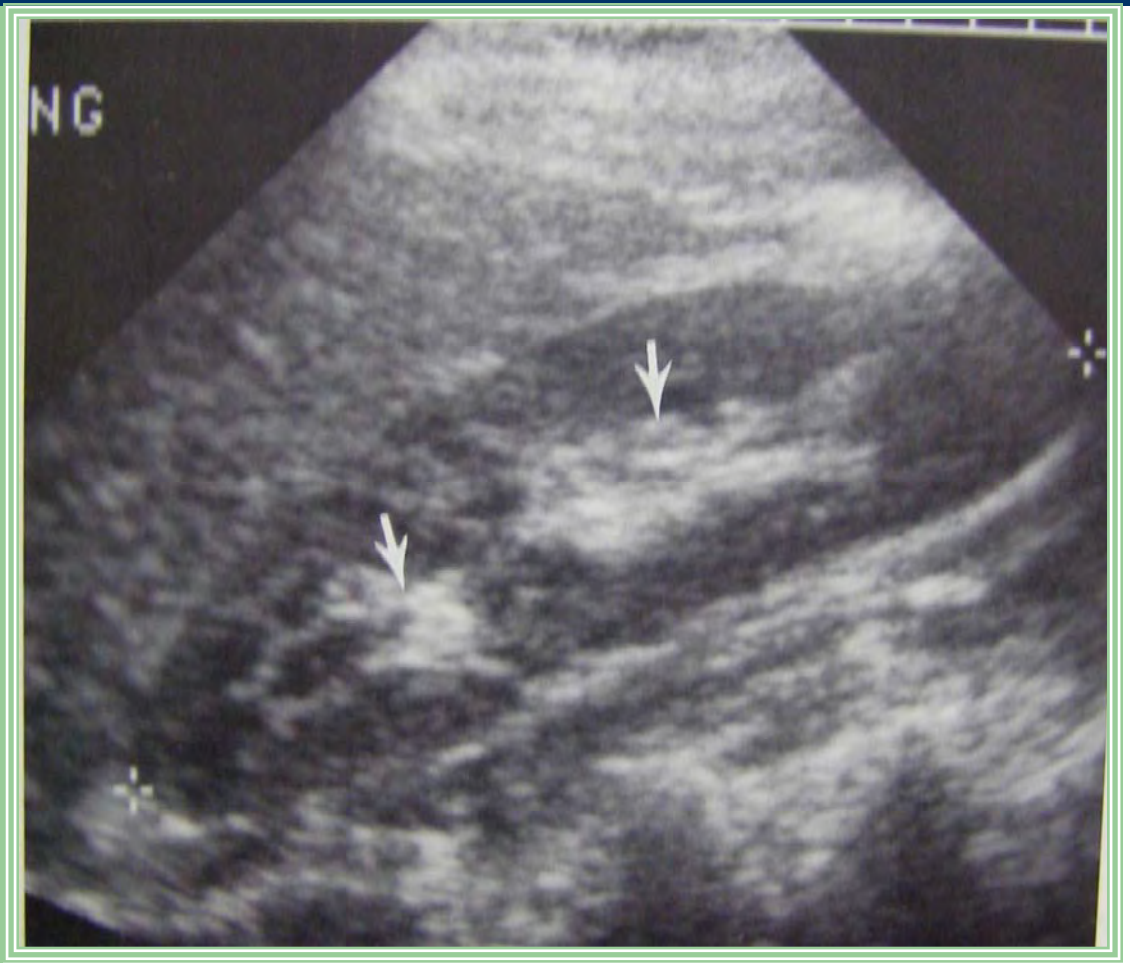

Pyelonephritis

- Normal
- ↑ size & echogenicity
- Thickening of the wall of renal pelvis & calyceal distortion

Cortical scar

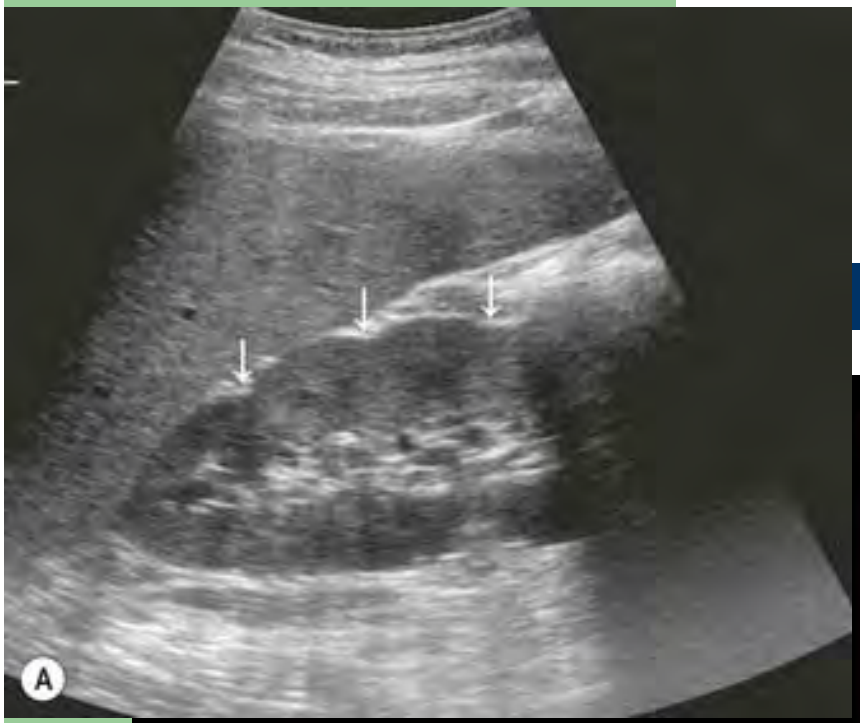

KEYPOINTS:
Scar- linear echogenic line from the cortical edge in towards a pyramid

*1 .- Smooth **transition** with the capsule*

*2 .- **Continue** with the perirrenal fat*

*3 .- Does **not cause** mass effect*

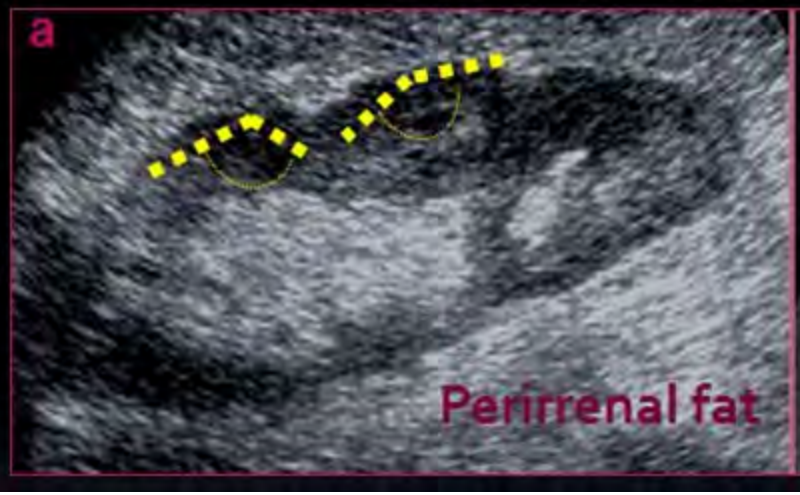

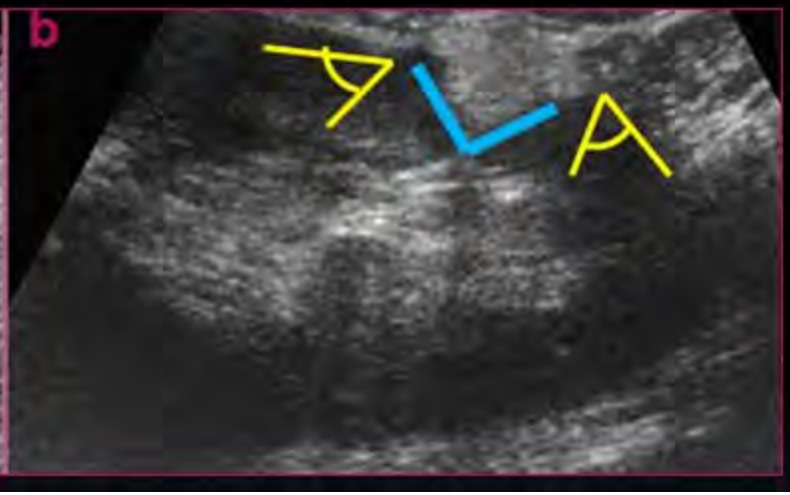

- In both the neonatal and paediatric kidney, the foetal cortical lobulations are pronounced and should span the pyramids
- If a lobulation dips into a pyramid, it is likely to be a cortical scar

Pyonephrosis
(dilated system & echogenic content)

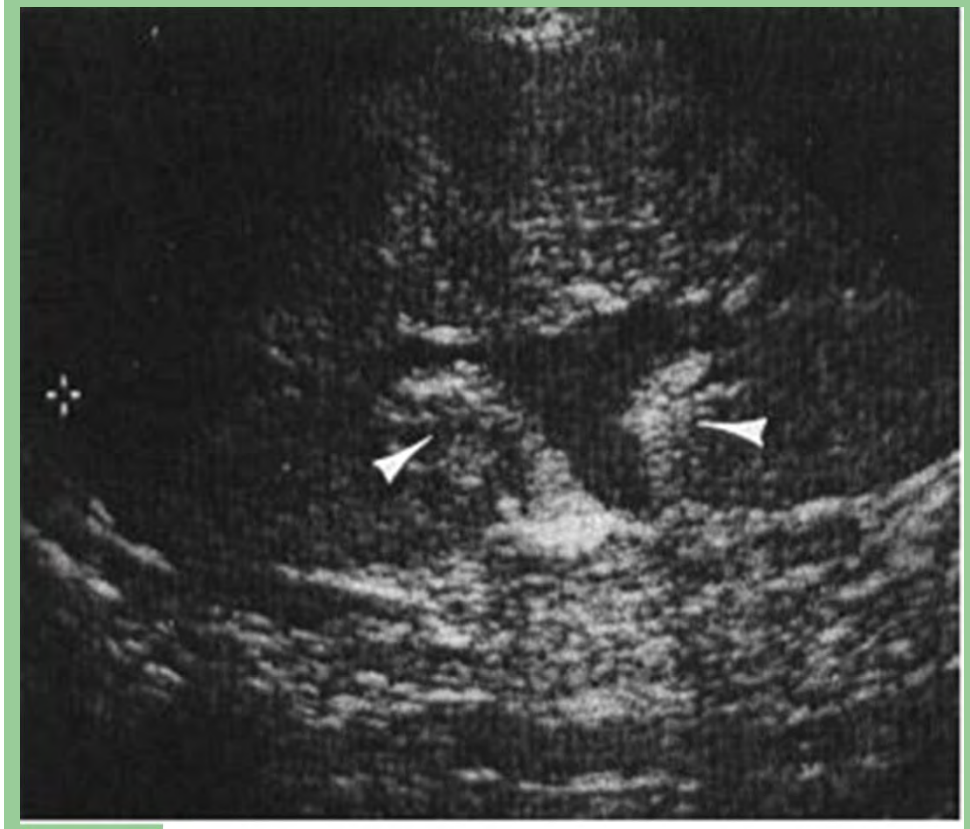

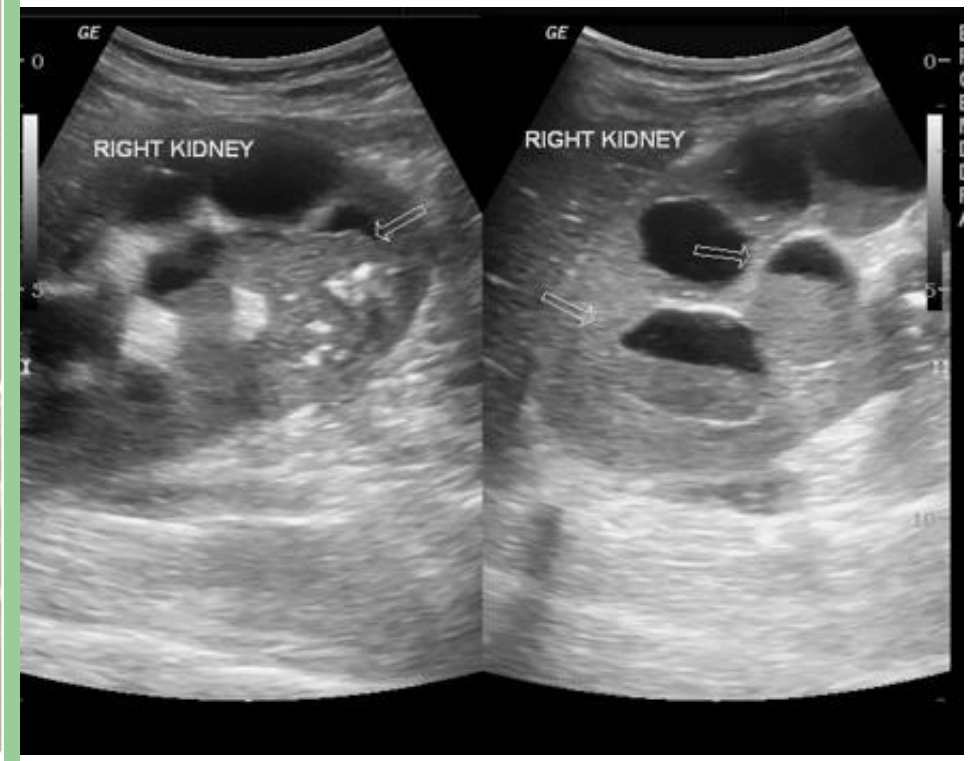

Stones

highly echogenic + acoustic shadowing

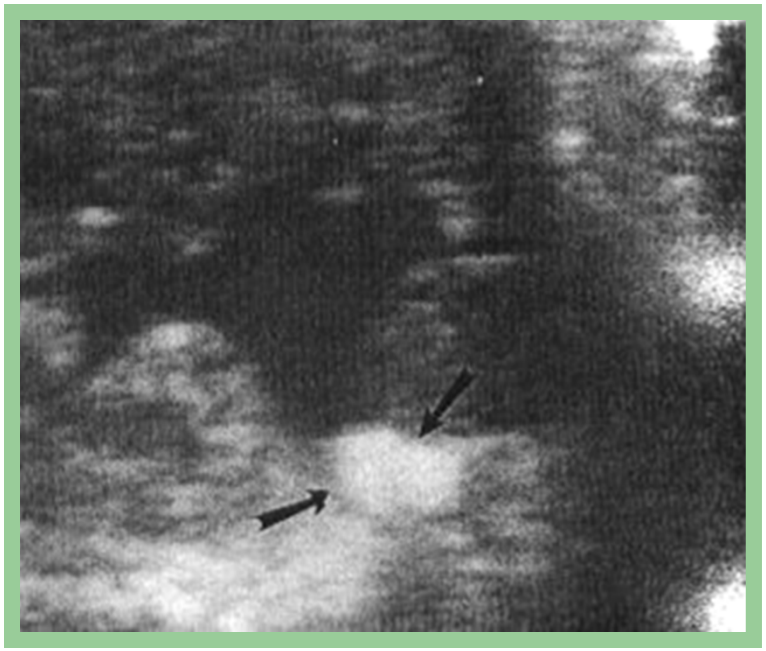

Stones

highly echogenic + acoustic shadowing

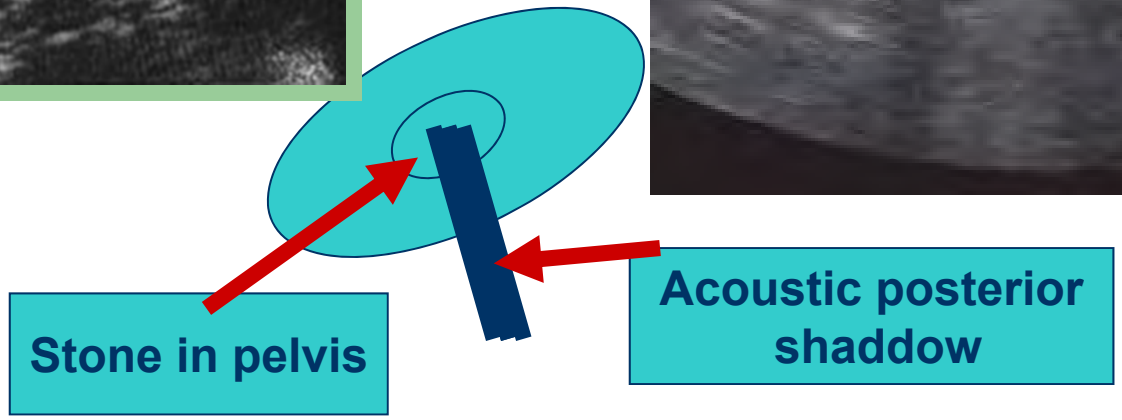

Nephrocalcinosis

- Calcium deposition in the renal parenchyma
- Medullary ➔ hyperechoic pyramids
- Diffuse ➔ ↑ cortical & medullary echog.

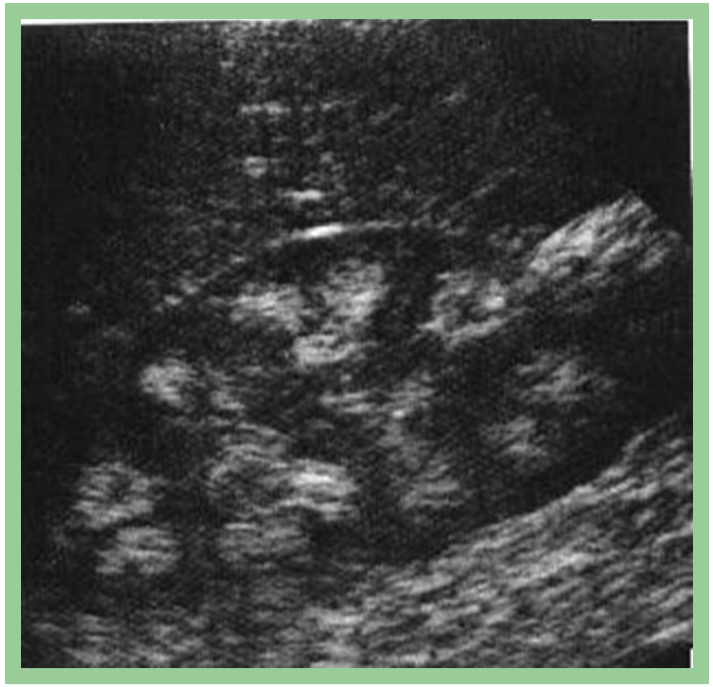

Nephrocalcinosis

Causes:

- Idiopathic hypercalciuria
- Long term furosemide therapy in neonates esp. premature
- Hypervitaminosis D
- Hyperparathyroidism
- Renal tubular acidosis
- Hyperoxaluria
- Medullary sponge kidney

Other causes of hyperechoic medullary pyramids:

- Tamm Horsfall proteins
- Vascular congestion
- Papillary necrosis.
- Transient in neonate with oliguria & perinatal anoxia.

Cystic renal diseases

RENAL FAILURE

http://informahealthcare.com/rnf
ISSN: 0886-022X (print), 1525-6049 (electronic)

Ren Fail, Early Online: 1–7
© 2014 Informa Healthcare USA, Inc.
DOI: 10.3109/0886022X.2014.883996

inform healthcare

CLINICAL STUDY

Clinical and ultrasonographical characterization of childhood cystic kidney diseases in Egypt

Neveen A. Soliman[1,2], Marwa M. Nabhan[1,2], Hafez M. Bazaraa[1,2], Ahmed M. Badr[1,2], and Mohamed Shaheen[3]

[1]*Department of Pediatrics, Center of Pediatric Nephrology & Transplantation, Kasr Al Ainy School of Medicine, Cairo University, Cairo, Egypt,* [2]*Egyptian Group for Orphan Renal Diseases (EGORD), Cairo, Egypt, and* [3]*Department of Radiology, Kasr Al Ainy School of Medicine, Cairo University, Cairo, Egypt*

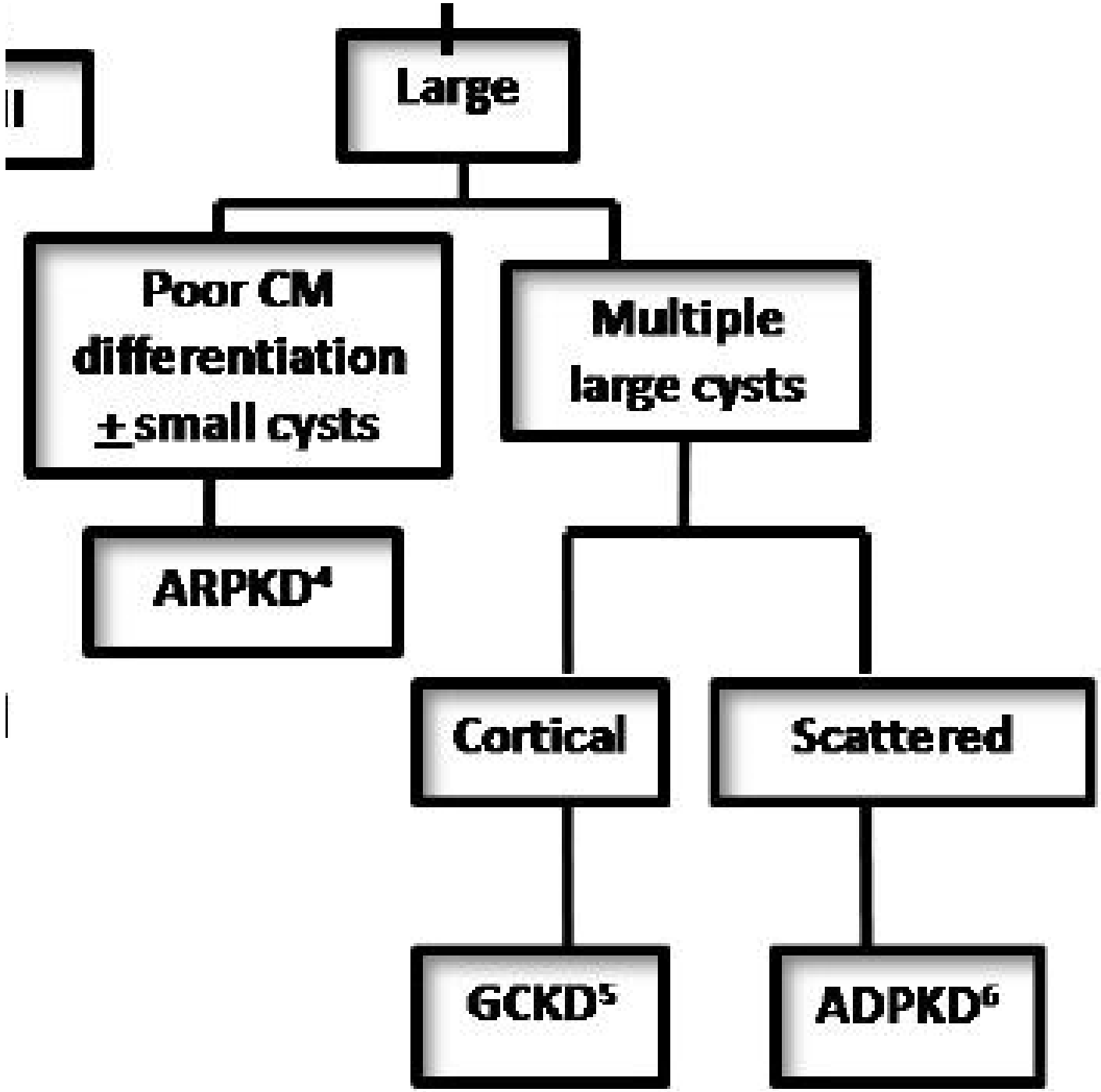
Large
Poor CM differentiation ±small cysts
Multiple large cysts
ARPKD[4]
Cortical
Scattered
GCKD[5]
ADPKD[6]

Renal Cystic disease

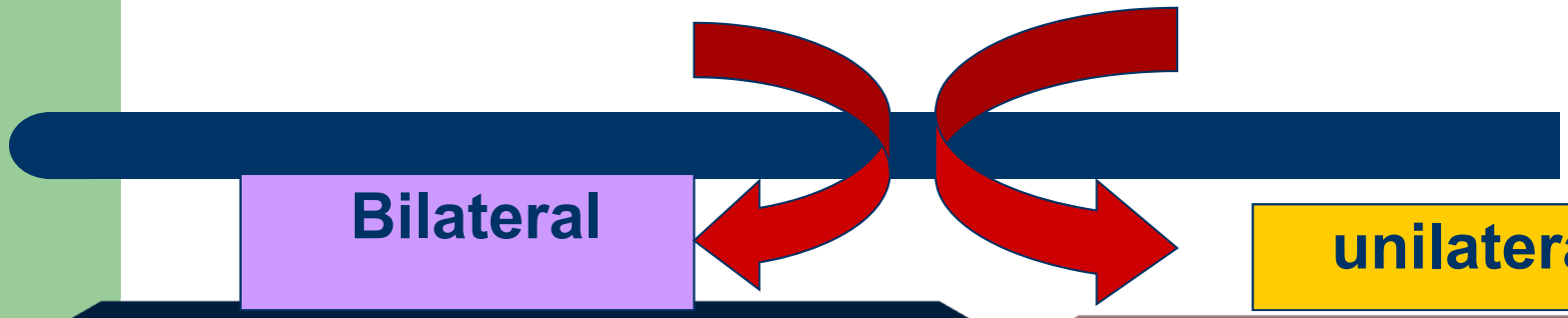

Bilateral

- AR polycystic Kid
- AD polycystic Kid
- Glomerulo Cystic Disease
- Cysts associated with multiple malformation syndrome (e.g.) Turner syndrome Tuberous sclerosis.
- Cystic disease of renal medulla

unilateral

- Simple Cyst.
- Multi Cystic Dysplasia.
- Multilocular Cystic nephroma

Polycystic Kidney Disease

A.R	A.D.
▪ Multiple small cysts1-2mm (dilated collecting tubules) ▪ Congenital hepatic fibrosis (presented later).	▪ Large cysts are present in both kidneys . ▪ Congenital hepatic fibrosis is rare
▪ <u>By ultrasound</u> ▪ Bilateral enlarged echogenic kidneys with poor delineation of the renal sinus , medulla and cortex.	▪ <u>By ultrasound</u> ▪ <u>In neonates</u> the same as A.R.polycystic kidney. ▪ In old child : multiple larg cysts in both kidneys
▪ Presented in neonatal. ▪ Period with → ↓ kidney function	Presented in 4th or 5th decade with hypertension or hematuria. <u>Rarely</u> in neonate presented with Abd. Mass.

ADPKD

CRITERIA
3+ total @15-39y
2+ each kid. @40-59y
4+ each kid. @60y+
<2 @40y + EXCLUDES

ARPKD

Complete medullary involvement

No cortical involvement

Mildly enlarged kidney

Preserved cortex

Significant echogenic renal medulla

ARPKD


ITAL CLINIC -BARCELONA-
ABDOMEN
10:59:14
S37-4.2
40Hz
0°
5/2
50/0
5/ 00
14.4cm

Multicystic-Dysplastic Kidney

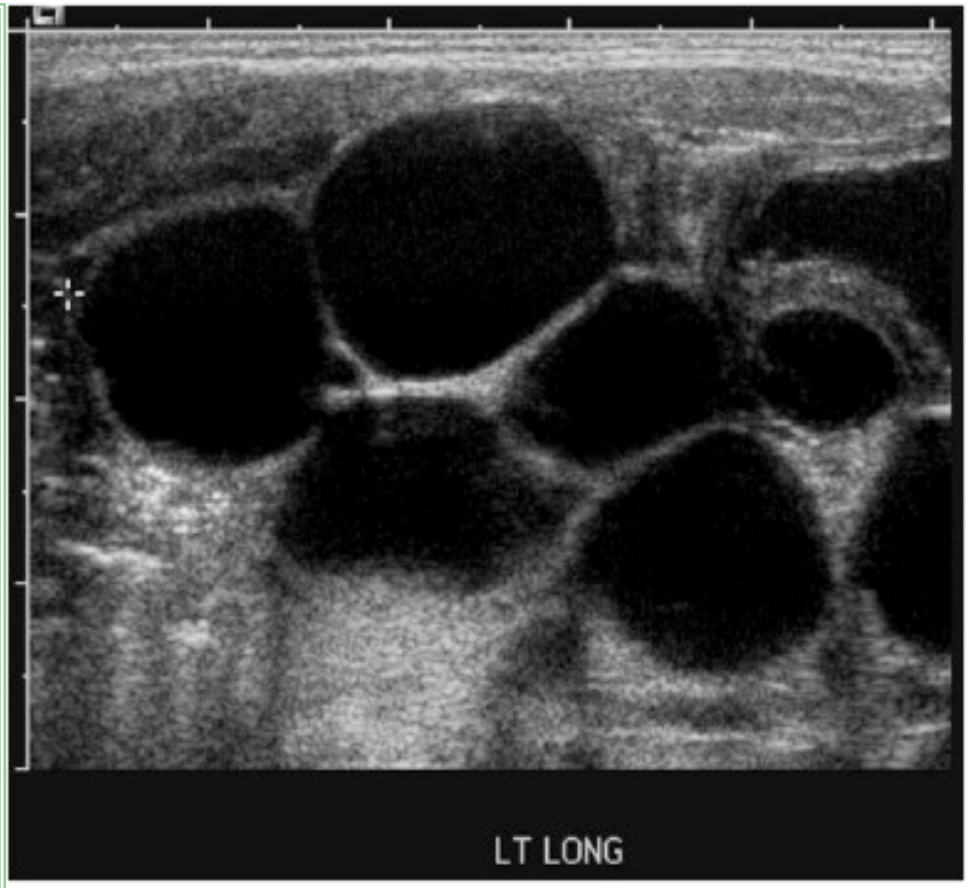

Bladder

- Urine
- Wall thickness (3mm full, empty: 5mm but may give false impression of ↑)
- Chronic ↑ pressure or infection
- Defects, stones, focal thickening, etc
- Lower ureter

Scanning: Bladder

- Begin in transverse with a slight caudal angle. Sweep trough the bladder for any structural defects or focal wall thickening.
- Distal ureteric dilatation, Ureteroceles, ureteric jets by Doppler.
- Post-voiding residual urine

Thick Bladder Wall

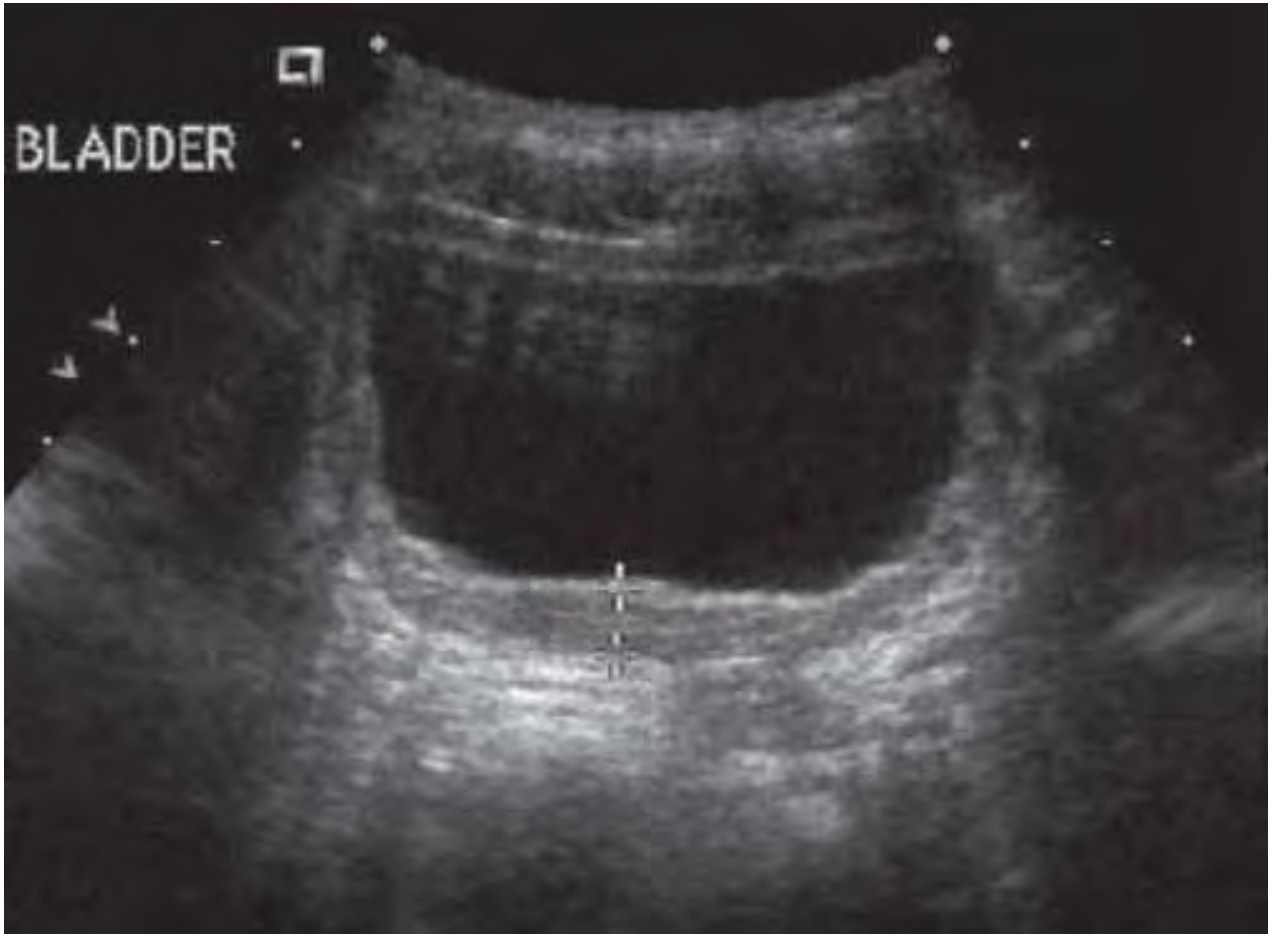

Bladder hematoma (post-biopsy)

Cystitis

- Diffuse thickening of bladder wall
- with extensive involvement, the inflammatory lesion can protrude into bladder lumen → mimiking Rhabdomyo sarcoma of bladder
- Diff by → cystoscopy or follow up after treatment of infection

PUV

- The most common cause of uretheral obst in boys.
- By ultrasound → → →
  - Bilateral hydronephrosis & Hydroureter
  - Thick bladder wall

Ureterocele

Congenital or infl. Obstruction ureter near trigone➔ ballooning just proximal ➔ ‘intravesical’ mass with thin sonolucent wall

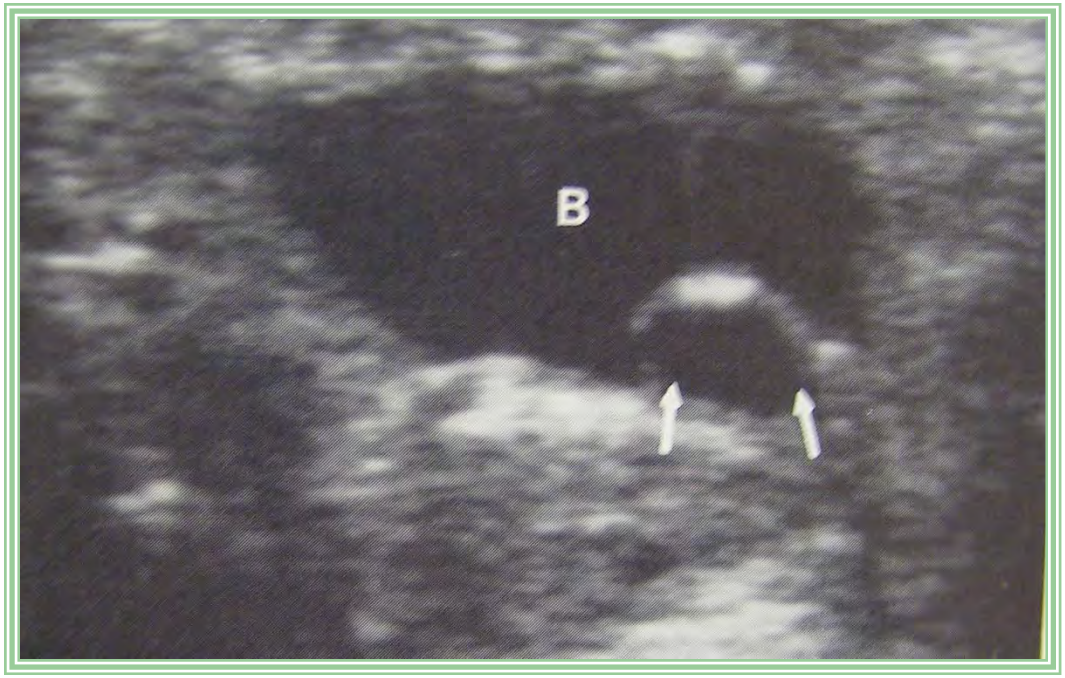

Mega ureter

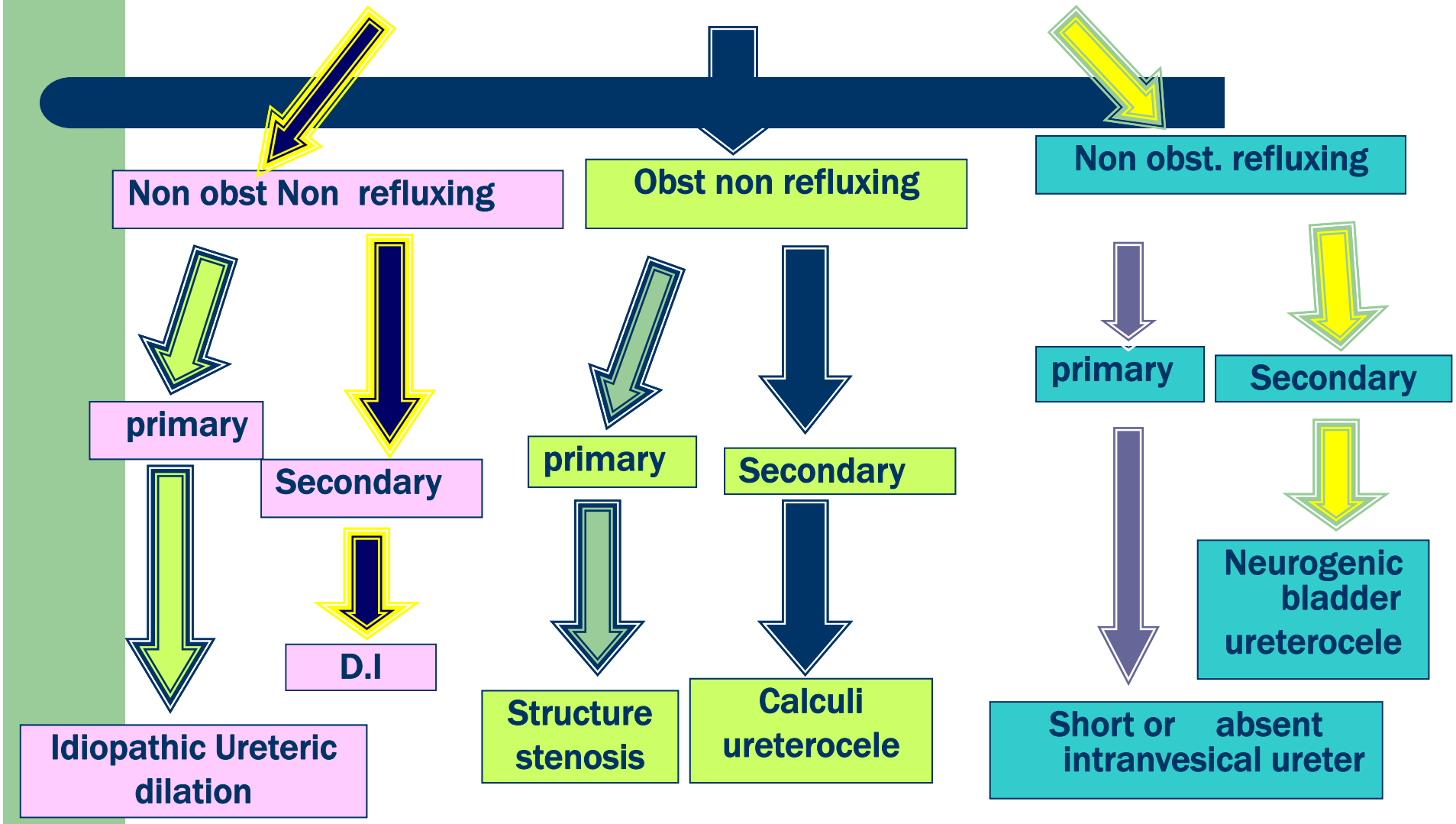
Non obst Non refluxing
Obst non refluxing
Non obst. refluxing
primary
Secondary
primary
Secondary
primary
Secondary
D.I
Neurogenic bladder
ureterocele
Idiopathic Ureteric dilation
Structure stenosis
Calculi ureterocele
Short or absent intranvesical ureter

Special techniques

- Doppler imaging
  - Renal vessels
  - Ureteric jets
- Voiding urosonography (contrast/ Doppler)
- Post-voiding residual urine

Doppler imaging

*Arterial *Venous *Perfusion

• PSV	< 180 cm/sec
• Renal Aortic Ratio (RAR)	< 3
• Resistive index (RI)	< 0.70
• Δ RI (right – left)	< 0.05
• Acceleration Time (AT)	< 0.07 sec
• Acceleration Index (AI)	> 3.5 m/s^2

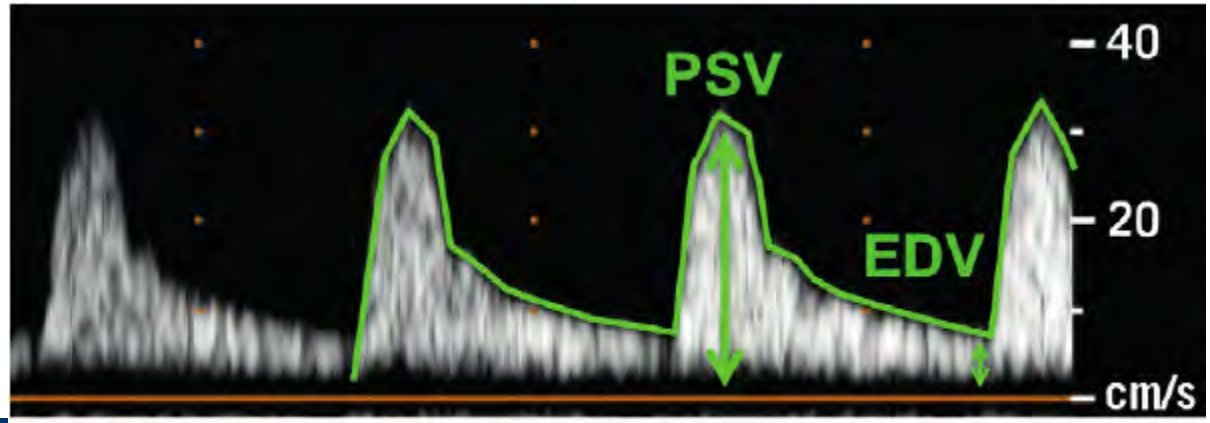

Resistance index=1–(V_{min}/V_{max})

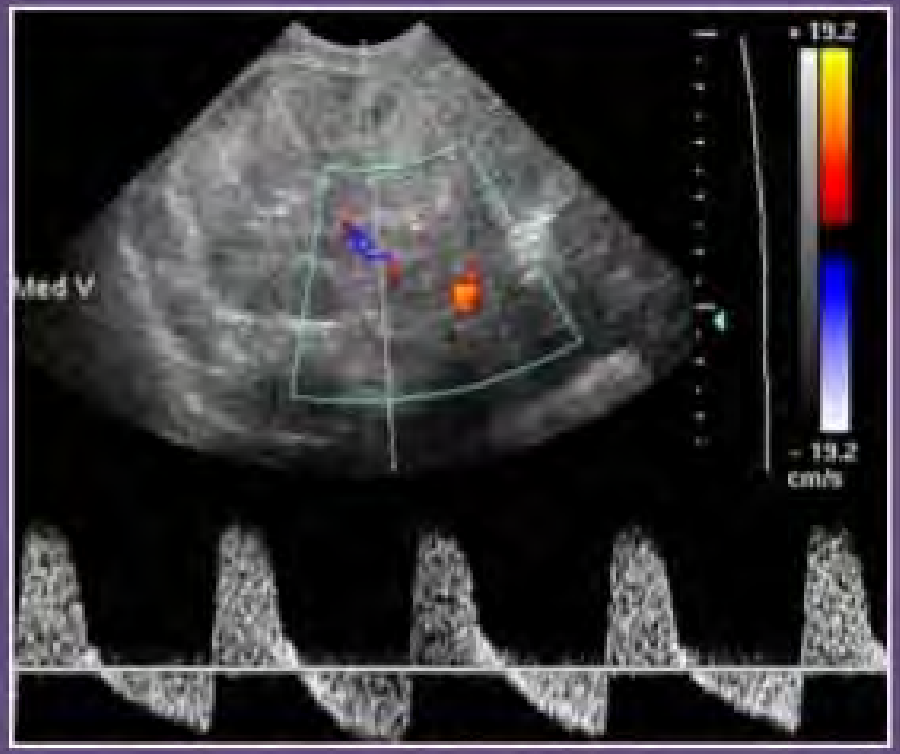

Reversed diastolic flow in main renal artery

RVT: enlarged echog (oedema)

Ureteric jets by Doppler

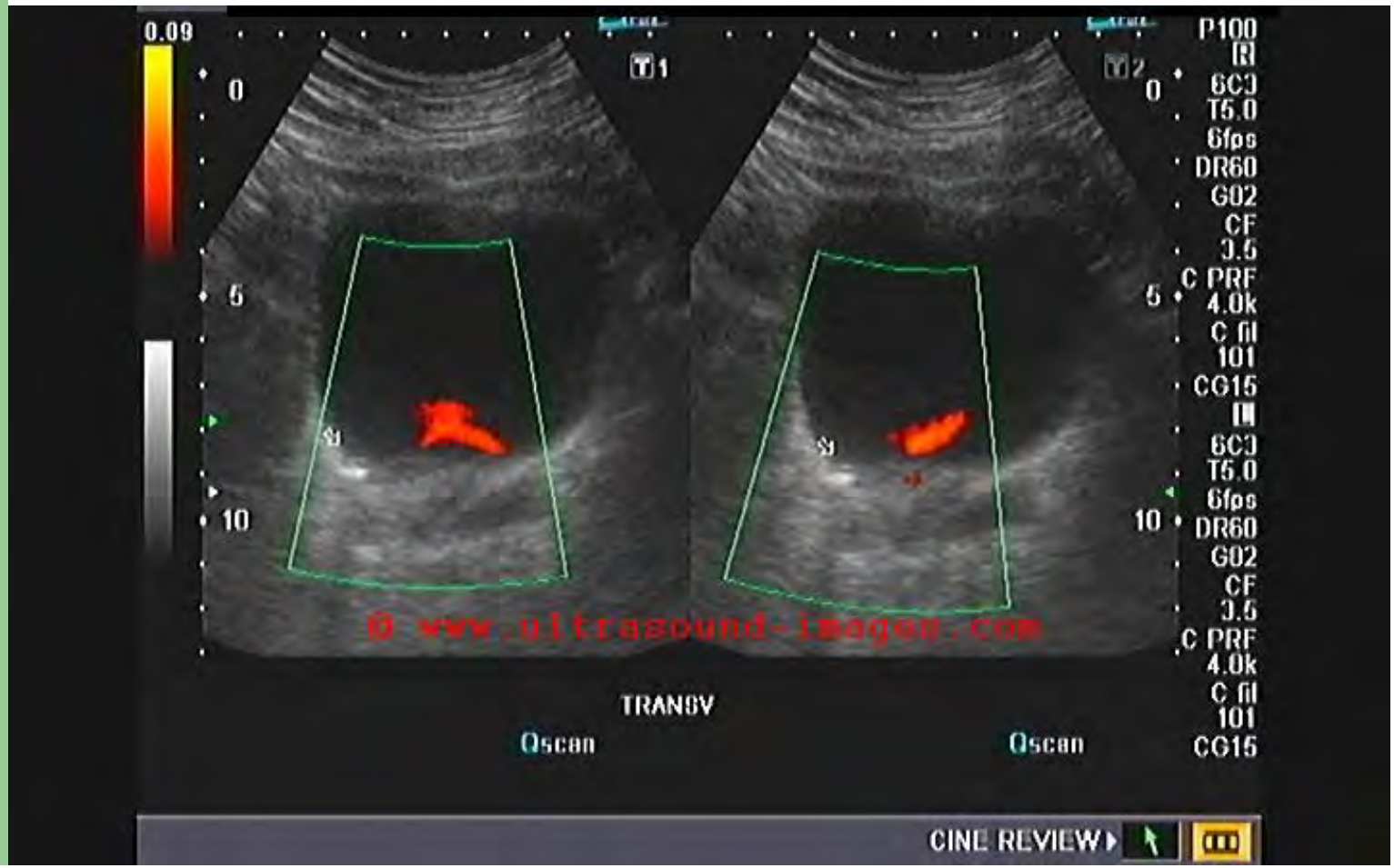

Other roles of U/S

- **Interventional Nephrology**
  Biopsies, CVCs, etc
- **Critical care nephrology**

Therefore …

- **Ultrasound is the principal imaging modality for visualization of the kidneys & urinary tract**
- **Clinical examination & diagnostic tests are increasingly being integrated**

  Remember ABG, CBG, dipstick, POC-testing, CXR, ….
- **A basic ultrasound examination can add a lot to a nephrology assessment**

  And can guide further imaging/ investigation if needed


Thank you

1. Multicystic dysplastic kidney is usually associated with

A multiple communicating renal cysts

B liver cysts

C polyhydramnios

D no uptake on isotopic scan

2. A neonate with unilateral hugely dilated renal pelvis without ureteric dilatation is most probably having

A vesicoureteric reflux

B pelviureteric obstruction

C posterior urethral valve

D ureterocele

3. Compared to older children, neonatal kidneys generally feature

A larger size

B increased echogenicity

C highly echogenic renal sinus

D absent renal pyramids